

## Randomized controlled trial of fractionated laser resurfacing on aged skin as prophylaxis against actinic neoplasia

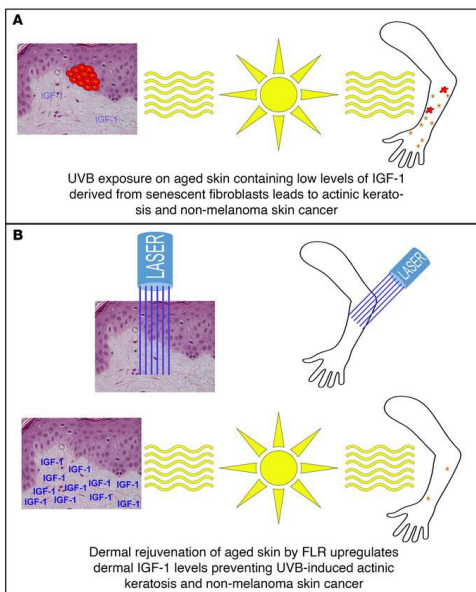
Dan F. Spandau, ... , Robert Hoopes, Jeffrey B. Travers

*J Clin Invest.* 2021;131(19):e150972. <https://doi.org/10.1172/JCI150972>.

Clinical Medicine

Dermatology

### Graphical abstract



Find the latest version:

<https://jci.me/150972/pdf>



# Randomized controlled trial of fractionated laser resurfacing on aged skin as prophylaxis against actinic neoplasia

Dan F. Spandau,<sup>1,2,3</sup> Roy Chen,<sup>4</sup> Jeffrey J. Wargo,<sup>5</sup> Craig A. Rohan,<sup>4,5</sup> David Southern,<sup>2</sup> Angela Zhang,<sup>2</sup> Mathew Loesch,<sup>2</sup> Jonathan Weyerbacher,<sup>2</sup> Sunil S. Tholpady,<sup>3,6</sup> Davina A. Lewis,<sup>2</sup> Matthew Kuhar,<sup>2,7</sup> Kenneth Y. Tsai,<sup>8</sup> Amber J. Castellanos,<sup>4</sup> Michael G. Kemp,<sup>4</sup> Michael Markey,<sup>5</sup> Elizabeth Cates,<sup>4</sup> Amy R. Williams,<sup>4</sup> Christina Knisely,<sup>4</sup> Sabina Bashir,<sup>4</sup> Ryan Gabbard,<sup>4</sup> Robert Hoopes,<sup>4</sup> and Jeffrey B. Travers<sup>4,9,10</sup>

<sup>1</sup>Department of Biochemistry and Molecular Biology and <sup>2</sup>Department of Dermatology, Indiana University School of Medicine, Indianapolis, Indiana, USA. <sup>3</sup>Richard L. Roudebush Veterans Administration Medical Center, Indianapolis, Indiana, USA. <sup>4</sup>Department of Pharmacology & Toxicology and <sup>5</sup>Department of Dermatology, Boonshoft School of Medicine at Wright State University, Dayton, Ohio, USA. <sup>6</sup>Department of Surgery and <sup>7</sup>Department of Pathology, Indiana University School of Medicine, Indianapolis, Indiana, USA. <sup>8</sup>Departments of Anatomic Pathology and Tumor Biology, Moffitt Cancer Center, Tampa, Florida, USA. <sup>9</sup>Department of Biochemistry and Molecular Biology, Boonshoft School of Medicine at Wright State University, Dayton, Ohio, USA. <sup>10</sup>Dayton Veterans Administration Medical Center, Dayton, Ohio, USA.

**BACKGROUND.** The loss of insulin-like growth factor 1 (IGF-1) expression in senescent dermal fibroblasts during aging is associated with an increased risk of nonmelanoma skin cancer (NMSC). We tested how IGF-1 signaling can influence photocarcinogenesis during chronic UVB exposure to determine if fractionated laser resurfacing (FLR) of aged skin, which upregulates dermal IGF-1 levels, can prevent the occurrence of actinic keratosis (AK) and NMSC.

**METHODS.** A human skin/immunodeficient mouse xenografting model was used to test the effects of a small molecule inhibitor of the IGF-1 receptor on chronic UVB radiation. Subsequently, the durability of FLR treatment was tested on a cohort of human participants aged 65 years and older. Finally, 48 individuals aged 60 years and older with considerable actinic damage were enrolled in a prospective randomized clinical trial in which they underwent a single unilateral FLR treatment of one lower arm. Numbers of AKs/NMSCs were recorded on both extremities for up to 36 months in blinded fashion.

**RESULTS.** Xenografting studies revealed that chronic UVB treatment with a topical IGF-1R inhibitor resulted in a procarcinogenic response. A single FLR treatment was durable in restoring appropriate UVB response in geriatric skin for at least 2 years. FLR resulted in sustained reduction in numbers of AKs and decreased numbers of NMSCs in the treated arm (2 NMSCs) versus the untreated arm (24 NMSCs).

**CONCLUSION.** The elimination of senescent fibroblasts via FLR reduced the procarcinogenic UVB response of aged skin. Thus, wounding therapies are a potentially effective prophylaxis for managing high-risk populations.

**TRIAL REGISTRATION.** ClinicalTrials.gov (NCT03906253).

**FUNDING.** National Institutes of Health, Veterans Administration.

## Introduction

Keratinocyte carcinomas, also known as nonmelanoma skin cancers (NMSCs), are the most common human neoplasm (1, 2). Though rarely lethal in immunocompetent populations, NMSCs and precursor actinic keratosis (AK) lesions are associated with considerable morbidity, and treatment often incurs a high economic impact (3). In contrast, NMSCs (especially squamous cell carcinomas) cause considerable mortality in immunodeficient

populations, particularly solid organ transplant recipients (4). It is accepted that advanced age and UVB wavelengths found in sunlight are the primary risk factors for acquiring NMSC and AK (5, 6).

Recent data have led to a new paradigm to explain the role of aging in NMSC carcinogenesis (7). The appropriate response of keratinocytes to acute UVB exposure is to avoid cellular replication in the presence of continuing UVB-induced DNA damage. In contrast, aged keratinocytes exhibit an inappropriate UVB response in which cellular replication occurs despite the persistence of DNA damage. The inappropriate UVB response in aged keratinocytes is due to an increased presence of senescent fibroblasts in geriatric dermis, which results in the silencing of insulin-like growth factor 1 (IGF-1) expression in the skin (8). This finding is supported by documented differences in senescent

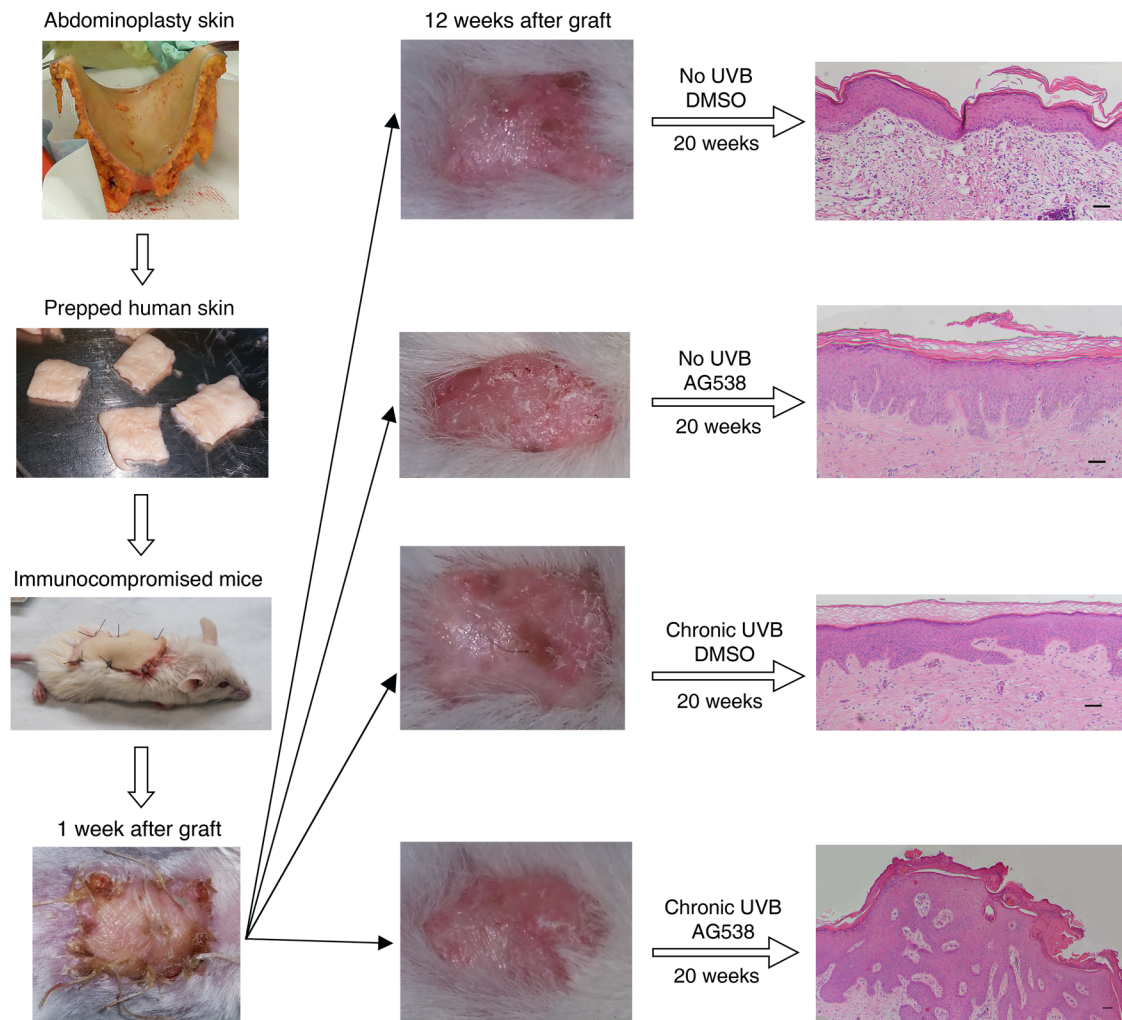
**Conflict of interest:** The authors have declared that no conflict of interest exists.

**Copyright:** © 2021, American Society for Clinical Investigation.

**Submitted:** April 29, 2021; **Accepted:** August 18, 2021; **Published:** October 1, 2021.

**Reference information:** *J Clin Invest.* 2021;131(19):e150972.

<https://doi.org/10.1172/JCI150972>.



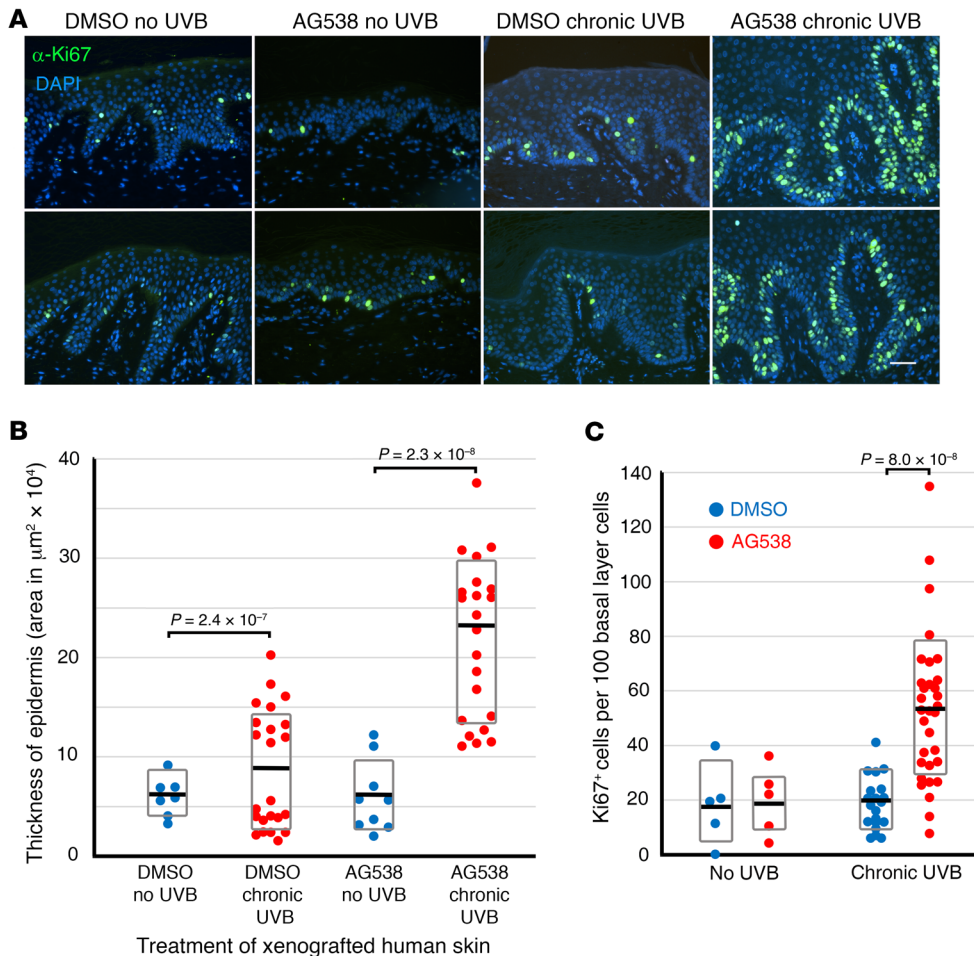
**Figure 1. Inhibition of the IGF-1R on human skin leads to phenotypic UVB-induced hyperproliferative lesions in the skin.** Human skin obtained from discarded abdominoplasty surgeries was grafted onto immunodeficient mice (11). The human skin was topically treated with vehicle or 20  $\mu$ M AG538, a small molecule inhibitor of the IGF-1R. Thirty minutes after treatment, the mice were irradiated with 700  $\text{J}/\text{m}^2$  of UVB, 5 days a week for 20 weeks (AG538 was applied twice a week before UVB irradiation). Representative H&E images of the human skin. Scale bars: 50  $\mu\text{m}$ . Note: the scale bar in the chronic UVB AG538 treatment group (lower right) is much smaller than the other 3 images.

fibroblasts and IGF-1 levels between participants aged 65 and older versus younger counterparts (8). Moreover, aged skin responds to acute UVB treatment such that geriatric basal keratinocytes coexpress the proliferation marker Ki67 as well as UVB-induced thymine dimers, a finding not seen in participants aged younger than 30 years. Furthermore, this abnormal response to acute UVB is reversed by either exogenous dermal injections of IGF-1 or wounding of skin to upregulate IGF-1 levels (8–10).

The appropriate UVB response, by which IGF-1 receptor (IGF-1R) activation protects against keratinocyte malignant transformation, has been shown to occur through at least 3 distinct mechanisms. First, IGF-1R activation on keratinocytes upregulates the expression of multiple DNA repair enzymes (11). Second, the transient suppression of DNA synthesis following UVB, understood to be a protective mechanism to allow the cell to repair damaged DNA before proliferation, is mediated by IGF-1 (12). Finally, IGF-1R activation promotes senescence of proliferating basal keratinocytes which cannot repair DNA damage, a process

that protects the body against cells with fixed mutations (8). Thus, aging results in a deficient activation of the IGF-1R in epidermal keratinocytes due to diminished *IGF-1* expression from dermal sources, causing an inappropriate UVB-response in these cells and leading to proliferation of these keratinocytes containing DNA damage (Ki67+:thymine dimer+ basal keratinocytes), which ultimately leads to photocarcinogenesis.

Consistent with this new paradigm that fibroblast senescence expressing decreased levels of IGF-1 underlie these procarcinogenic effects, wounding of geriatric skin with dermabrasion or fractionated laser resurfacing (FLR) removed senescent fibroblasts, increased *IGF-1* levels to those found in young adult skin, and normalized acute UVB responses (9, 10). However, these previous studies only treated a small area ( $\sim 5 \times 5$  cm) of either forearm or buttock skin in 65-year-old or older volunteers and only examined responses at 3 months after wounding. The safety, efficacy, and durability of a single treatment with ablative fractionated resurfacing laser on forearm/dorsal hand in aged individuals



**Figure 2. Hyperproliferation of human epidermis induced by UVB is exacerbated by inhibiting the IGF-1R.**

Human skin obtained from discarded abdominoplasty surgeries was grafted onto immunodeficient mice and treated as described in Figure 1. These results were obtained from 3 biological replicates, each time containing groups of at least 4 mice per treatment. **(A)** Representative sections of human skin xenografts were stained with antibodies to the proliferation marker Ki67 (SP6 clone) and nuclei identified by DAPI staining. **(B)** Sections of skin stained with H&E were digitized and the area of the epidermis and length of the basement membrane were determined using Nikon Elements software. The relative thickness of the epidermis was then determined by dividing the area by the basement membrane length. Average areas indicated by black bars and standard deviation represented by gray boxes (DMSO no UVB, 8 images; DMSO chronic UVB, 12 images; AG538 no UVB, 7 images; AG538 chronic UVB, 16 images). **(C)** Sections of human skin stained with  $\alpha$ -Ki67 as in **C** were imaged and quantified for Ki67(+) cells using Nikon Elements software. Black bars indicate averages and gray boxes represent the standard deviation of counts from 5 images (no UVB controls), 20 images (DMSO, chronic UVB), or 32 images (AG538, chronic UVB). *P* values shown derived from 2-tailed Student *t* test. The absence of *P* values indicates a lack of statistically significant difference between data shown.

with multiple AKs at high risk for NMSC is at present unknown. Furthermore, previous studies have demonstrated the potential for increased susceptibility to the development of skin cancer due to the inactivation of IGF-1R signaling, but it has not been clearly demonstrated. To that end, the overall goal of the current studies is to define the role of dermal fibroblast senescence with concomitant loss of IGF-1 in photocarcinogenesis. First, we used what we believe is a novel xenografting model to assess the effect of mimicking aged human skin using a topical IGF-1R inhibitor on chronic UVB responses. Next, the long-term effects of FLR on geriatric skin *IGF-1* levels and acute UVB responses were assessed. Finally, a randomized prospective clinical trial where high-risk par-

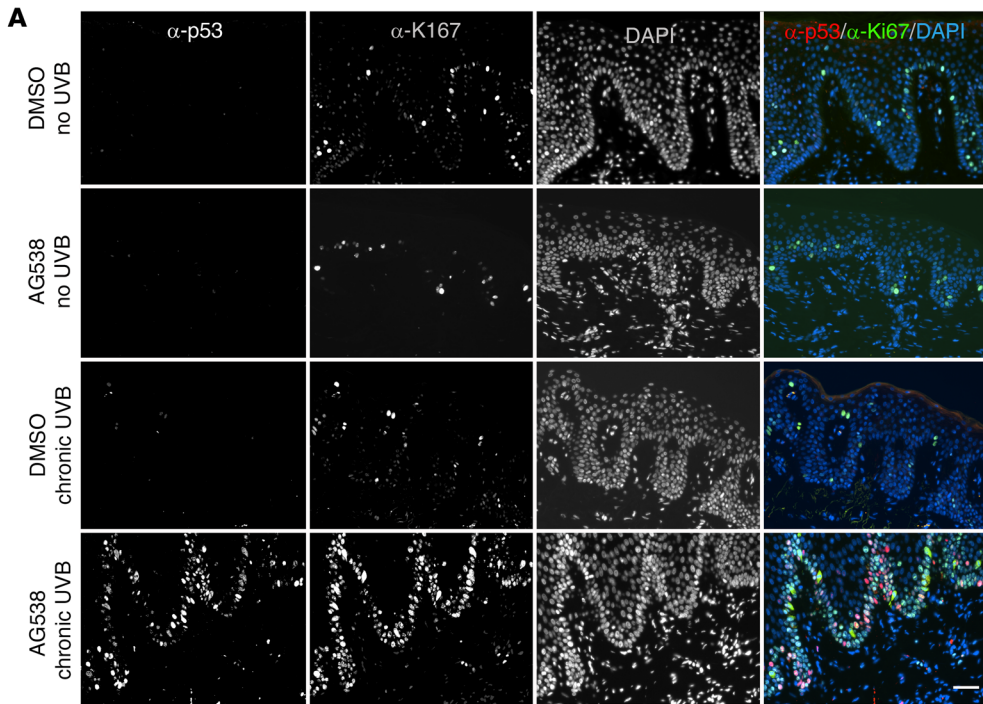
ticipants underwent FLR to one extremity was initiated, with the outcomes being AKs and NMSCs.

## Results

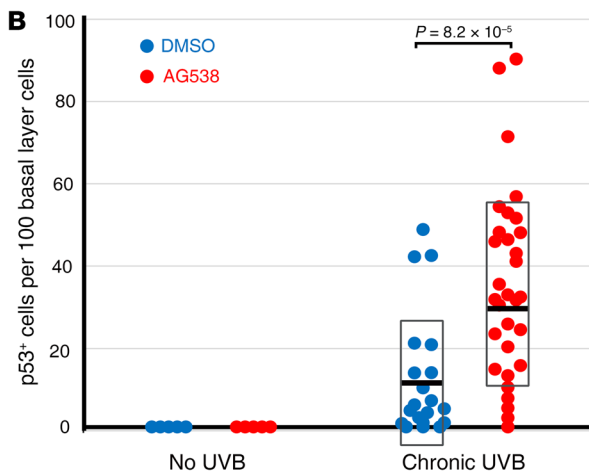
*Aging of human skin in vivo leads to UVB-induced epidermal hyperplasia and photocarcinogenic initiation.* Murine models have been extremely valuable in photocarcinogenesis studies (13). However, important differences in the expression pattern of IGF-1 in human and mouse skin render normal UVB mouse protocols unworkable in examining our model system (14). Unlike human keratinocytes, IGF-1 is abundantly expressed in murine epidermis by keratinocytes (14). In contrast, the major source of IGF-1 for human keratinocytes is stromal tissue, predominantly dermal fibroblasts. Therefore, to test the role of IGF-1R signaling in the chronic UVB responses in vivo, we used a validated human skin xenograft model (Figure 1, Figure 2, Figure 3, ref. 11, and Supplemental Figure 1; supplemental material available online with this article; <https://doi.org/10.1172/JCI150972DS1>) using immunodeficient mice. To simulate the silencing of IGF-1R signaling seen in geriatric human skin in this model, some of the xenografts were topically treated with a small molecule inhibitor of the IGF-1R, AG 538 (8). Chronic sun exposure was approximated by irradiating the xenografted mice 5 times a week with 700 J/m<sup>2</sup> of UVB (close to 2 MEDs) for 20 weeks. As expected, control

human skin xenografts treated with the DMSO vehicle and chronic UVB exposure displayed increased undulation of the rete ridges and mild epithelial hyperplasia when compared with xenografts from unirradiated animals. In contrast, chronic UVB irradiation of human skin xenografts treated with the IGF-1R inhibitor yielded hyperplastic epidermal tissue with histological features of AKs (Figure 1). Furthermore, increased keratinocyte proliferation (as denoted by Ki67<sup>+</sup> cells) as well as nests of p53-positive keratinocytes were observed only in human skin treated with the IGF-1R inhibitor and chronic UVB (Figure 2 and Figure 3).

We also noted increased numbers of senescent fibroblasts in the papillary dermis of skin treated with our UVB source (9), which



**Figure 3. Inhibition of the IGF-1R on human skin leads to phenotypic UVB-induced malignant lesions in the skin.** (A) Representative sections of human skin xenografts were stained with antibodies to both Ki67 (green) and p53 (red; DO-7 clone). (B) Sections of human skin stained with α-p53 were imaged and quantified for p53+ cells using Nikon Elements software. Black bar indicates the average and gray boxes represent the standard deviation of counts from 5 images (no UVB controls), 20 images (DMSO, chronic UVB), or 31 images (AG538, chronic UVB). P values shown are derived from 2-tailed Student t test.

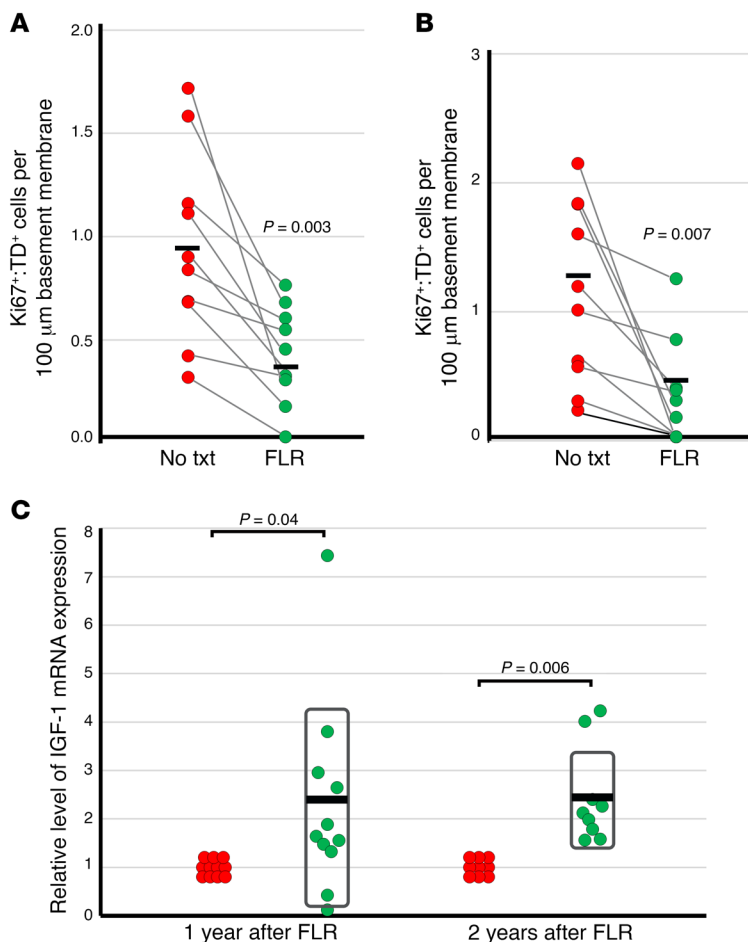


was accentuated in AG538-treated skin (Supplemental Figure 2). Histologic assessment by of hematoxylin and eosin-stained slides (supplemented by slides stained with antibodies to Ki67 or p53) by dermatopathologists in blinded fashion revealed features consistent with premalignant AK only in the chronic irradiated skin treated with IGF-1R inhibitor. These findings provide support for the concept that human skin lacking IGF-1R signaling responds in a procarcinogenic manner to UVB.

*Durability of wounding response in aged skin in vivo promoting the appropriate UVB response.* Previous studies by our group have documented that aged skin treated with either dermabrasion or FLR results in a decreased proportion of senescent fibroblasts, increased levels of IGF-1 mRNA, and normalization of the procarcinogenic response of Ki-67+/TD+ basal keratinocytes at 3 months following the wounding therapy (9, 10). To define the durability of this response, we conducted a randomized clinical trial by recruiting groups of volunteers with nondiabetic Fitzpatrick skin types I

and II, age 65 and older, and treated a 5 × 5 cm area of either the dorsal forearm (sun-exposed) or hip/buttock (sun-protected) skin. The study was conducted between April 2014 and May 2017. For demographic details of the participants, see Supplemental Table 1. FLR treatment of geriatric skin in vivo led to a decrease in the number of proliferating keratinocytes containing UVB-damaged DNA (increasing the appropriate UVB response, Figure 4, A and B) following acute UVB exposure as compared with control skin and a corresponding increase in the expression of IGF-1 mRNA (Figure 4C) in FLR-treated geriatric skin. The responses were similar at both 1 and 2 years after wounding, indicating that the wounding response resulted in a stable long-term dermal effect.

*FLR treatment removes existing AKs and prevents the occurrence of de novo AKs.* Aged (≥ 60 years old) participants were enrolled in a randomized prospective clinical trial to test the effect of FLR on AK development between January 2018 and April 2021 (Figure 5). Due to the demographic limitations of a Veterans Administration



**Figure 4. FLR leads to lasting protection from inappropriate UVB responses in geriatric skin.** At 1 (**A**) or 2 (**B**) years following treatment with FLR to localized areas of skin, geriatric volunteers were UVB irradiated at the site treated with FLR and at an untreated control site. Biopsies were removed 24 hours after UVB exposure and assayed for the presence of basal layer cells that expressed both the proliferative marker Ki67 and markers of UVB-induced DNA damage (thymine dimers [TDs]; clone KTM53). In **A** and **B**, each dot represents a participant and lines between the No Txt and FLR columns indicate results from the same volunteer. Solid dark lines indicate the mean. Ten participants were analyzed for either 1 year or 2 years after FLR. FLR-treated sites demonstrated a significant reduction in double-labeled cells compared with untreated sites ( $P < 0.007$ , Student *t* test) at both 1 and 2 years after FLR. (**C**) The relative level of IGF-1 mRNA in each biopsy was determined by QPCR, standardized using the expression of the housekeeping gene  $\beta$ 2-microglobulin. The black bar indicates the average and gray boxes represent the standard deviation of assays from 11 individuals (1 year after FLR) or 9 individuals (2 years after FLR). *P* values shown are derived from 2-tailed Student *t* test.

dermatology clinic, only 1 female and 47 male participants were enrolled. Inclusion criteria included existing actinic damage to wrists and forearms, and having a minimum of 5 AKs present on each arm. As shown in Figure 6A, one arm was randomly chosen for FLR treatment from the elbow extending on the dorsal surface to the metacarpal-phalangeal joint. Prior to FLR treatment, the number and location of AKs on each arm was recorded. The number of AKs on FLR-treated arms was not significantly different than the number of AKs on untreated arms (treated arms:  $7.64 \pm 3.5$  AKs versus untreated arms:  $6.26 \pm 2.9$  AKs). Though the treatments resulted in significant levels of wounding (Figure 6B), minimal discomfort and no scarring was noted in the participants. Side effects from laser treatment were obtained by self-report. Pain, crusting, and epidermal change all resolved within 2 weeks following treatment. Erythema resolved within 1 month following treatment.

Participants were examined at 3 months following FLR treatment and every 6 months thereafter. The number and location of each AK was documented and lesions suspected of malignant transformation were excised and submitted to dermatopathology for diagnosis. Table 1 contains demographic data on the participants and the medical history of previous skin cancer diagnoses. This is an ongoing study, and the number of return visits by participants is shown in Table 1. We previously reported outcomes for 30 of these participants at 3 and 6 months following FLR treatment (15). Subsequent to that report, 18 additional participants were recruited to the study.

To determine the effectiveness of FLR in reducing the occurrence of AKs, the ratio of the number of AKs documented on FLR-treated arms to the numbers of AKs on untreated arms was determined (Figure 6C). This ratio, determined before FLR treatment on day 0 (1.32), reflects the randomness of AKs occurring on each extremity (equal numbers of AKs on each arm would yield a ratio of 1.0). There was a slight bias for development of AKs on the left arm (7.3 AKs) versus the right arm (6.5 AKs), but this difference was not statistically significant ( $P = 0.09$ , Student *t* test). At 3 months after FLR treatment, the ratio of AKs on treated versus untreated arms was reduced 4 fold ( $P = 1.7 \times 10^{-23}$ , Student *t* test). Throughout the current 36-month follow-up period, the ratio has been maintained; in fact, none of the ratios determined at 3, 6, 12, 18, 24, 30, or 36 months after FLR are significantly different. As described in our first report on this cohort, these data indicate that FLR is an effective treatment for existing AKs (15). However, our model predicts that FLR treatment will also prevent the occurrence of new AK lesions. Two separate analyses were used to model the initiation of new AK lesions. Figure 6E represents data on the 20 participants observed thus far at 30 months after FLR treatment. On day 0, the red (untreated) and blue (FLR-treated) data points are interspersed equally, reflecting the randomness of AK occurrence. However, subsequent data points reflect a segregation of AK occurrence dependent on FLR treatment. If the slope of each set of individual data points is determined, a positive slope indicates increasing numbers of AKs over time, while a negative slope spec-

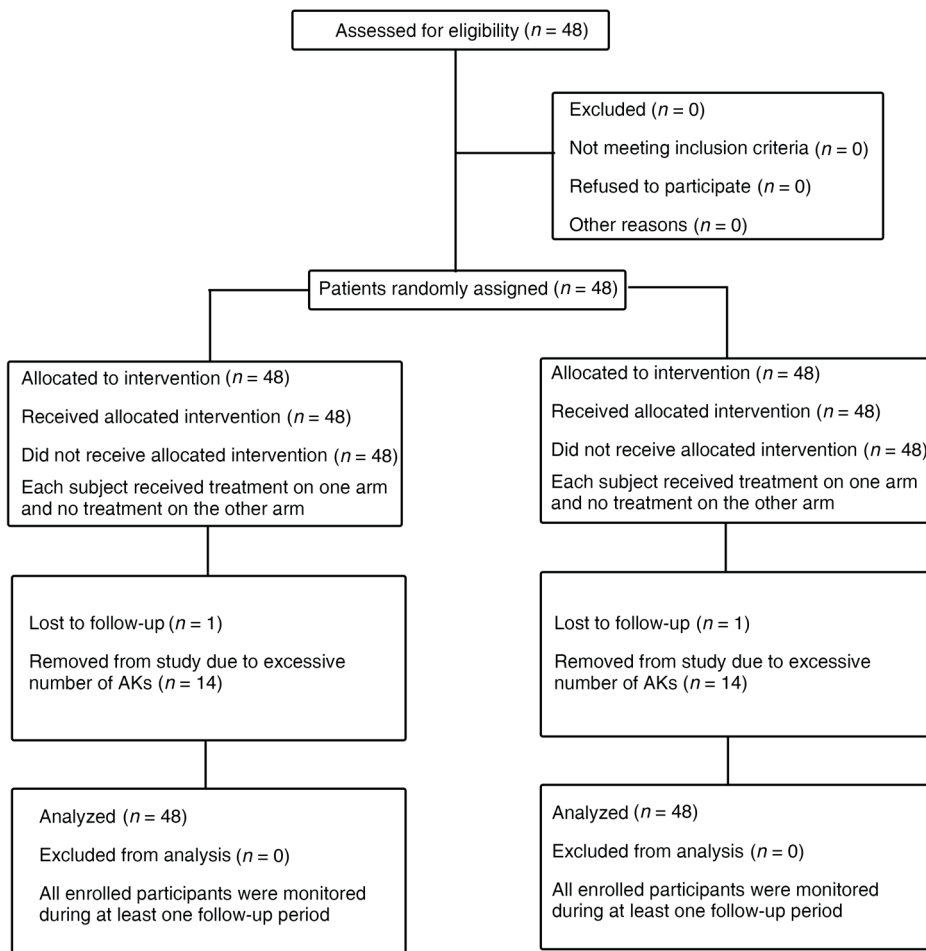


Figure 5. CONSORT flow diagram for prospective, randomized, controlled clinical trial.

ifies decreasing numbers of AKs (a slope of 0 equals no change in AK numbers). As seen in Figure 6D, untreated arms continue to accumulate increasing numbers of AKs (a slope of 0.19). In contrast, AKs on FLR-treated arms are decreasing with time, indicating the lack of newly initiated lesions (a slope of -0.04, see also Supplemental Figure 3 for data representing other time points).

A second analysis of the data posits that if FLR were only removing existing lesions, one would predict that the number of AKs that were present at 3 months on both untreated and FLR-treated arms would accumulate at the same rate subsequent to the 3 month time point. As shown in Figure 7A, the number of AKs on untreated arms continues to accumulate at a faster rate than those found on FLR-treated arms. These data again suggest that FLR treatment is decreasing the initiation of new AK lesions (Figure 7B). Fourteen participants were removed from the study (2 individuals at 12 months; 1 individual at 18 months; 9 individuals at 24 months; 1 individual at 30 months; 1 individual at 36 months; Table 1) as they were found to have 20 or more AKs; all excessive numbers of AKs were on untreated arms. The excessive number of AKs these participants acquired suggests that they had excessively photodamaged skin at the onset of the study. However, when the 14 participants who were withdrawn from the study were compared with the 34 active participants, there was no statistical dif-

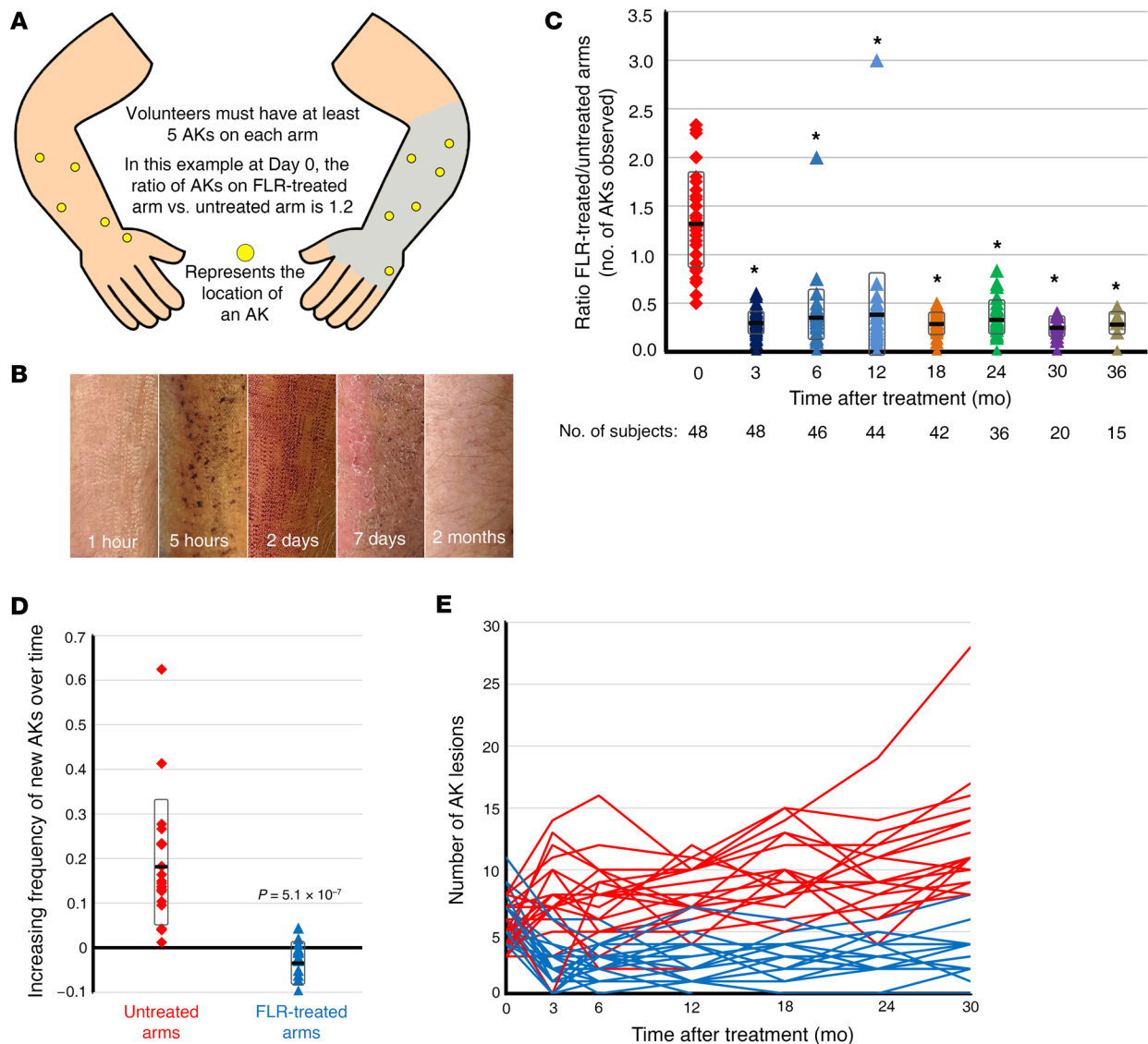
ference in the numbers of AKs in their initial screening (Supplemental Figure 4A). Of interest, there was no difference in how the participants forced to withdraw from the study due to excessive AKs on their untreated arms responded to FLR treatment when compared with the participants still actively enrolled in the study. These participants were then treated with field therapy of topical 5-fluorouracil cream or topical photodynamic therapy.

*FLR treatment reduces the occurrence of NMSCs.* While AKs are a precursor lesion to squamous cell carcinoma (SCC), not all AKs will progress into malignant lesions (16). Therefore it is important to examine the occurrence of NMSCs following FLR treatment. Consistent with the notion that FLR was preventing new actinic neoplasia, we noted a dramatic difference in numbers of NMSCs diagnosed in the untreated ( $n = 24$ ) versus FLR-treated ( $n = 2$ ) extremity (Figure 8A and Table 2). The majority of the NMSCs diagnosed by histology were SCC (11 invasive SCC and 8 SCC in situ on untreated arms; 1 SCC and 1 SCC in situ on FLR-treated arms), with lesser numbers (5) of basal cell carcinomas (BCCs) all on untreated arms (Table 2). Thus far, 16 of the 48 individuals enrolled in the study have developed confirmed NMSC (Table 2

and Figure 8B). NMSCs were only found on the untreated arms of 14 individuals. Two individuals have multiple tumors, including 1 each on their arms treated with FLR (participant 19 had 2 NMSCs on his untreated arm and 1 on his FLR-treated arm; participant 30 had 1 NMSC on his untreated arm and 1 on his FLR-treated arm). In total, 5 participants have developed multiple NMSC lesions on their untreated arms, while no participant has had more than 1 NMSC on their FLR-treated arm (Figure 8E). The frequency of the occurrence of NMSC with the total number of AKs detected was determined at each observation milestone (0, 3, 6, 12, 18, 24, 30, and 36 months). The average frequency of NMSC on untreated arms was 0.78%. In contrast, the frequency of NMSC on FLR-treated arms was significantly lower at 0.19% (Figure 8C). Similarly, when the frequency that any participant would have a NMSC diagnosis at a given observation period was determined, there was a significant difference between untreated and FLR-treated arms (Figure 8D). These studies indicate that a dermal wounding strategy involving FLR, which upregulates dermal IGF-1 levels, not only treats AKs, it prevents further development of AKs and NMSCs.

## Discussion

The most common class of cancers, NMSCs are associated with considerable morbidity from disfiguring surgeries as well as con-



**Figure 6. FLR prospective randomized clinical trial reveals decrease in total AK lesions and rate of accrual of new lesions.** Geriatric volunteers were required to have at least 5 AKs on each arm to be enrolled in the study. **(A)** On day 0, the number of AKs on each arm of geriatric volunteers was documented (represented by yellow circles in **A**). One arm was chosen, based on the last digit of the participant's social security number, to be treated with FLR on the dorsal surface from the elbow to the knuckles of the hand (gray shading). The other arm on each volunteer was not treated. **(B)** Representative clinical appearance of skin at various times after FLR. **(C–E)** The number of AKs on each arm of geriatric volunteers was documented (0 month, 48 participants) prior to FLR treatment on one arm. Participants were examined at 3 months (48 individuals), 6 months (46 individuals), 12 months (44 individuals), 18 months (42 individuals), 24 months (36 individuals), 30 months (20 individuals), and 36 months (15 individuals) to document AKs present on each arm. **(C)** The ratio of the number of AKs on FLR-treated arms to the number on untreated arms indicates a decrease in AK lesions following FLR treatment (ratio < 1.0). Heavy black bars denote means and gray boxes indicate standard deviations. Asterisks indicate significant difference between the follow-up time points and the 0 month ( $P < 10^{-12}$ ). Ratios determined at 3, 6, 12, 18, 24, 30, and 36 months were not statistically distinct. **(D)** At 30 months ( $n = 20$ ), the slope of the number of lesions over time was determined. A positive slope value represents increased numbers of AKs counted, and a negative number indicates decreasing numbers of AKs with time. Heavy black bars denote means and gray boxes indicate standard deviations.  $P$  values shown are derived from 2-tailed Student  $t$  test. **(E)** The number of AKs observed on both the FLR-treated and untreated arm over 30 months (total of 20 individuals).

siderable expense (2, 3). Extensive evidence has accumulated that indicates that aged skin is at increased risk for photocarcinogenesis, in fact the vast majority of NMSCs are diagnosed in individuals greater than 60 years of age (5, 6). Indeed, pioneering studies published almost 3 decades ago demonstrated that use of sunscreen protected against the acquisition of AKs and NMSCs provide support for the concept that photocarcinogenesis is an ongoing

process, not necessarily due to latency of carcinogenesis from previous UVB damage (17).

The metabolic and cytokine changes associated with fibroblast senescence have been well characterized (18, 19). Senescent fibroblasts exhibit decreased levels of cytokines such as IGF-1, yet exhibit increased secretion of classic proinflammatory cytokines, including interleukins IL-6, IL-8, and TNF- $\alpha$  (20). In the



**Table 1. Characteristics of participants in prospective study**

Total number in cohort	48
Number of males in cohort	47
Number of females in cohort	1
Average age of participant, years	74
Age range of participants, years	61–87
Number of participants with right arm treated	26
Number of participants with left arm treated	22
Participants with previous skin cancer diagnosis	
None	8
1–2 lesions	20
3–5 lesions	10
>5 lesions	10
Follow up data available for participants	
0 month	48
3 months	48
6 months	46
12 months	44
18 months	42
24 months	36
30 months	20
36 months	15
Participants withdrawn due to excessive numbers of AKs <sup>a</sup>	
12 months	2
18 months	1
24 months	9
30 months	1
36 months	1
Total	14

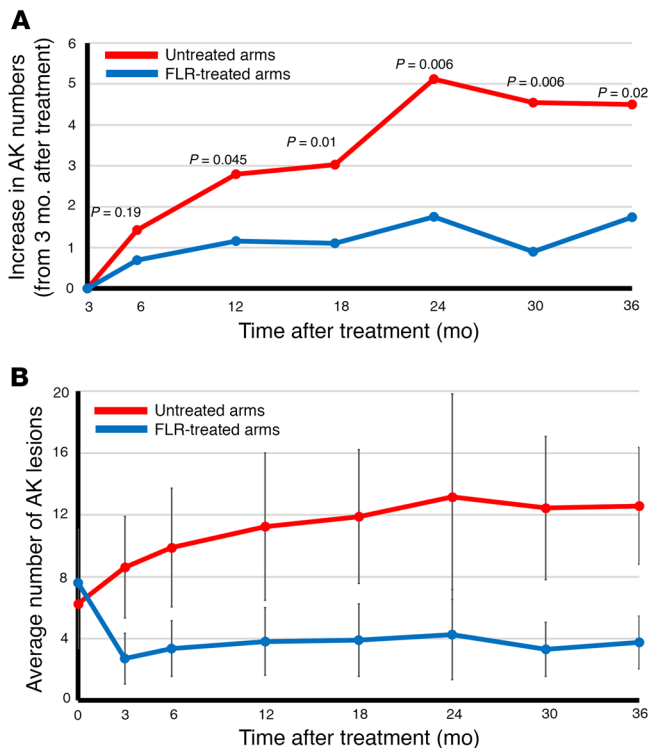
<sup>a</sup>Participants were removed from the study if more than 20 AKs were detected on 1 arm (all participants who were removed from the study were removed due to AKs on their untreated arms; range 20–30).

skin, senescent dermal fibroblasts have been found to accumulate with biological aging, accounting for up to 60% of the fibroblasts found in the papillary dermis (9). This increasing proportion of senescent fibroblasts in aged skin can influence how the epidermis maintains homeostasis and responds to environmental stresses. We have previously reported how the silencing of IGF-1 expression by senescent dermal fibroblasts can alter how epidermal keratinocytes respond to acute UVB exposure (8–12). However, it was unclear from those studies what the effect of inhibiting the activation of the IGF-1R in keratinocytes would have during long-term, repetitive exposure to UVB. In defining the IGF-1R-dependent inappropriate UVB response, we used primary normal human keratinocytes and fibroblasts grown as tissue culture monolayers (8, 21). While the use of *in vitro* cell culture is an excellent beginning to understanding how these cells respond to UVB irradiation, these experiments do not necessarily accurately represent how the intact 3D skin will react to UVB exposure. Moreover, the demonstration of dual-positive Ki67<sup>+</sup>/TD<sup>+</sup> basal keratinocytes following acute UVB exposure in an IGF-1-dependent manner in humans is important, yet UVB-induced carcinomas are believed to occur following chronic exposure to the UV components in sunlight (5). Therefore, the role of the IGF-1R in the UVB response of human

keratinocytes grown in 2D cultures needed to be verified on intact human skin. Previously, the induction of AKs and SCCs has been demonstrated on human skin xenografted in murine models; however, the detection of palpable lesions required daily UVB exposure for up to 2 years (22). If a chemical DNA mutagen was applied once prior to UVB exposure, the time required to observe actinic neoplasia was reduced to about 0.75 years (23). We can now report that inhibition of keratinocyte IGF-1R signaling accelerated the detection of AKs in our model at 20 weeks; approximately twice as fast as the rate when adding a chemical mutagen. We have previously demonstrated the efficacy of topical AG 538 to inhibit the keratinocyte IGF-1R using intact skin, and AG 538 has proven to be a reliable specific inhibitor of the IGF-1R (8). These studies validate the hypotheses that age-dependent inhibition of IGF-1R signaling contributes to UVB-induced carcinogenesis.

While in these studies we have focused on the importance of fibroblast renewal and the accompanying increase in IGF-1 expression following wounding, we do acknowledge that wound repair is an exceedingly complex process that involves many different factors and pathways. Any of these processes involving inflammatory factors, cytokines, other growth factors, lipid mediators, or cell adhesion and migration factors could be influencing or modifying the response of human keratinocytes to chronic UVB exposure. We also acknowledge that the role IGF-1 plays in preventing NMSC in the skin is incongruent with the established function IGF-1 has in promoting the growth of tumor cells in other tissues (24). Notably, it is the overexpression of IGF-1 that is associated with procarcinogenic effects in other tissues. In the skin, the wounding therapies are only restoring the levels of IGF-1 in geriatric tissues to normal levels found in young adult skin. It is worth noting that most IGF-1 distributed in the body is synthesized in the liver and carried in the circulatory system. However, the effects of IGF-1 in the skin are independent of liver-synthesized IGF-1 and subject primarily to only localized production of IGF-1 by dermal fibroblasts and some immune cells (25).

We previously reported in this cohort how using FLR field therapy can radically reduce the numbers of AKs within 3 months (15). This result is not unexpected as the procedure will remove premalignant cells. In fact, the importance of NMSCs has resulted in the adoption of many different field therapies for treatment of precursor AKs (26). Therapeutic options such as topical photodynamic therapy and 5-fluorouracil cream are designed to remove precancerous lesions and are effective, but they do not generate long-term dermal changes in the at-risk aged skin, which could result in sustained protection from actinic neoplasia. Within 6 to 12 months following the therapy, the number of AKs on treated skin rises to control levels. In contrast, there is a volume of literature, though much of it anecdotal, suggesting that wounding therapies used for cosmetic purposes appear to protect the recipient from AKs and NMSCs (27). The concept that wounding therapies could protect against NMSCs fits with the hypothesis that dermal fibroblast senescence with lack of IGF-1 plays an important role in the increased incidence of actinic neoplasia associated with aging (28). Importantly, we now report that FLR is a durable treatment for correcting the inappropriate UVB response in geriatric skin, maintaining efficacy for at least 2 years following treatment. However, the most critical data to emerge from our current studies are

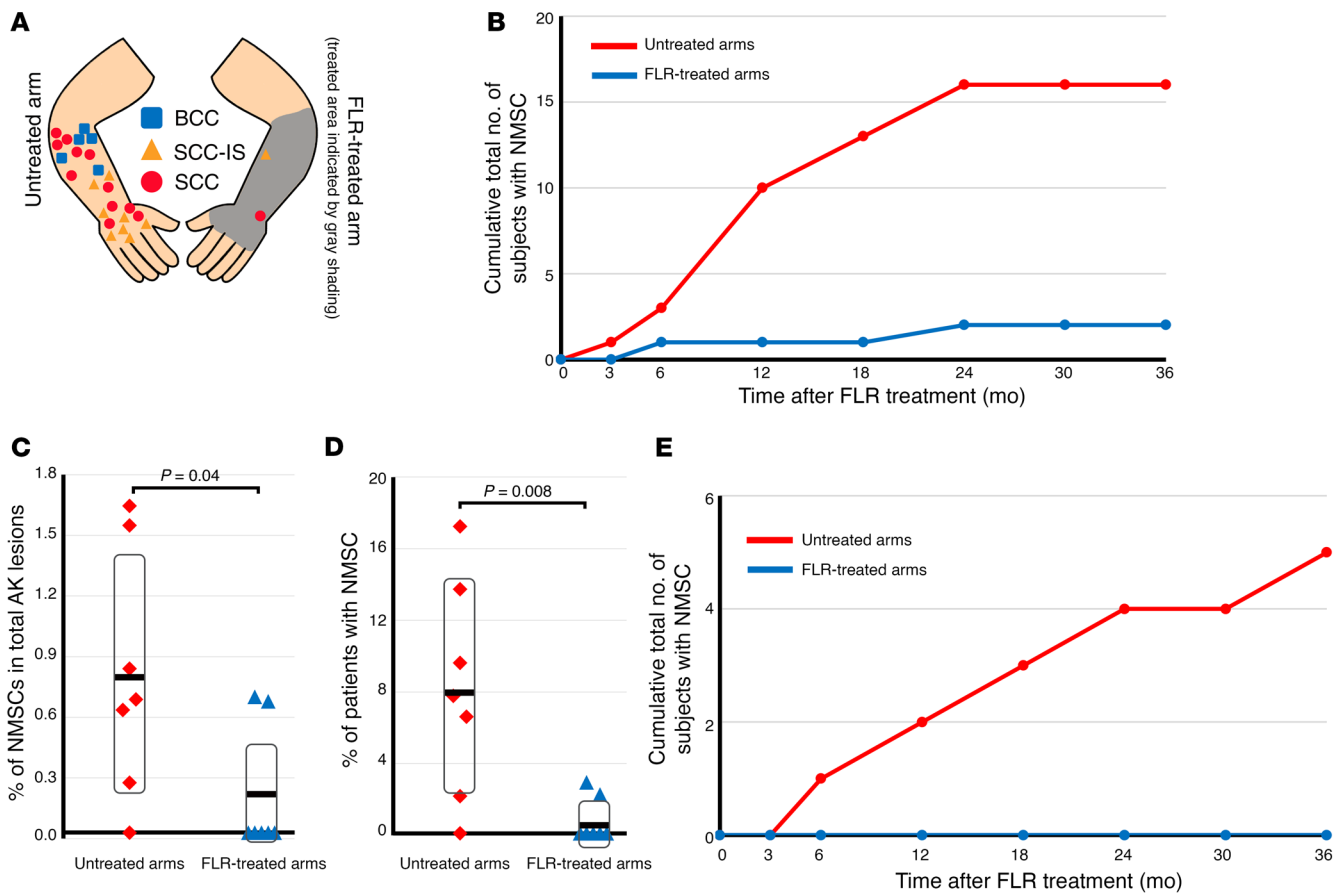


**Figure 7. FLR slows the rate at which new AK lesions appear. (A)** The change in the number of AK lesions since 3 months post-FLR treatment. Participants were examined at 3 months (48 individuals), 6 months (46 individuals), 12 months (44 individuals), 18 months (42 individuals), 24 months (36 individuals), 30 months (20 individuals), and 36 months (15 individuals). *P* values shown are derived from Student *t* test. **(B)** The average number of lesions on both untreated and FLR-treated arms was calculated using the sample numbers of individuals indicated in Figure 7A. Error bars represent the standard deviation. Student *t* test values for each time point were as follows: 0 months,  $P = 0.04$ ; 3 months,  $P = 8 \times 10^{-17}$ ; 6 months,  $P = 7 \times 10^{-15}$ ; 12 months,  $P = 4 \times 10^{-12}$ ; 18 months,  $P = 1 \times 10^{-11}$ ; 24 months,  $P = 6 \times 10^{-8}$ ; 30 months,  $P = 1 \times 10^{-6}$ ; 36 months,  $P = 1 \times 10^{-7}$ .

the functional inhibition of both AK and NMSC development by FLR for at least 36 months following a single treatment. There have been various estimates given for the probability of an AK to progress into a NMSC (specifically a cSCC), ranging from 5% to 10% (29) to as low as 0.1% (30), although the precise definitions for the frequency of SCC conversion often differs between studies. The frequency of NMSCs determined in untreated arms by our study (0.78%) is very similar to the 0.6% frequency described from a large study conducted in similar population (Veterans Administration [VA] patients, ref. 31). Following FLR treatment, the NMSC frequency falls 4-fold to 0.19%, perhaps indicating a reduction in the malignant potential of the remaining AKs on FLR-treated arms. Therefore, these data indicate that for individuals at high risk of developing NMSCs, a single treatment of FLR can provide lasting significant prevention of NMSCs. In the future, combined treatment with other proven systemic therapies such as nicotinamide (32) or calcipotriol (33) with FLR may prove to be even more effective. Of interest, the prior skin cancer history of the study participants did not correlate with how well FLR prevented the formation of AKs. This fact is important, as it indicates that the therapeutic use of FLR is not limited to a subset of individuals at the highest risk for skin cancer.

There are several limitations to the present studies. First, the human skin/mouse xenograft studies involved UVB exposures of the entire mouse, not just the human skin. Therefore, we cannot discount murine systemic responses to the UVB irradiation, which could influence the results. It should be noted, however, that the SCID/NOD mice used in the studies have fur, which would prevent direct exposure to the dorsal surface of the mouse skin. Second, the randomized interventional FLR study was performed at a single VA outpatient dermatology clinic that recruited predominantly males (47), with only one female recruited for the study.

The advantage of a VA population for these studies is that this population is rather stable, with the vast majority of the participants seeking all of their care through the VA system. However, due to the lack of females in our study group, we do not know if sex-based differences in IGF-1 expression, fibroblast senescence, or inflammatory profiles could influence the effectiveness of FLR treatment on our male cohort. We should note that a combination of female and male participants was analyzed in our previous studies examining how fibroblast senescence affects acute UVB irradiation in geriatric individuals and no gender-specific bias was observed. Third, the population recruited was at high risk for NMSCs, with at least 5 AKs on each forearm/dorsal hand. There is also an element of potential bias as the increased numbers of NMSCs identified in this population could be in part due to increased and focused surveillance as being in part of this study. Fourth, although the term geriatric has been arbitrarily used to define medical patients of at least 65 years old, it does not consider that not all individuals age at the same biological rate. Therefore, although we established a minimum age of 60 years old (ages ranged from 61 to 87 years old) for the prospective clinical study (65 years old for the clinical durability study), we must acknowledge that any large cohort of participants in this broad age group could have vastly different biological ages that do not match exactly with their chronological age. Finally, although FLR is only partially ablative and does not remove large areas of epidermis, it is possible that this procedure could be removing previously initiated keratinocytes. However, this interpretation of our data would not provide an explanation for the continued suppression of AK development observed at 36 months after wounding. Furthermore, one of the strengths of the study is the ability to use the same individual as both the experimental and the control subject. Collectively, the combination of human skin/murine xenograft and prospective wounding studies



**Figure 8. FLR reduces the occurrence of BCC and SCC in geriatric skin.** FLR treatment reduces the frequency of NMSCs arising from AKs as well as reduces the number of individuals who develop NMSCs. (A) Graphic representation of the location of BCC, SCC-in situ, and SCC identified on FLR-treated arms ( $n = 2$ ) and untreated arms ( $n = 24$ ). (B) The accumulation of verified NMSCs occurring on untreated and FLR-treated arms. (C) At each observation time point post-FLR treatment (3, 6, 9, 12, 18, 24, 30, and 36 months), the percentage of NMSCs that occurred out of the total number of AKs counted at the same time are shown for both untreated and FLR-treated arms. (D) At each time point described in C, the percentage of participants diagnosed with a NMSC is shown for both untreated and FLR-treated arms. For C and D, heavy black bars denote means and gray boxes indicate standard deviations. P values shown are derived from 2-tailed Student t test. (E) The cumulative total of participants who acquired more than 1 NMSC on their untreated arm. Thus far, no participant has more than 1 NMSC on their FLR-treated arm.

indicate that wounding therapies such as FLR could be part of a strategy to protect at-risk individuals against actinic neoplasia.

## Methods

**Chemicals/UVB.** All chemicals were obtained from Millipore/Sigma unless otherwise indicated.

**Xenografting studies.** Long-term xenografts from human skin were established on the dorsal surface of immunocompromised mice as previously reported (11). Briefly, under sterile conditions, the epidermis and superficial dermis were removed from an approximately  $2 \times 2$  cm area of the shaved, disinfected skin of 8- to 10-week-old female SCID/NOD (NOD/LtSz-scid/scid; obtained from breeding stock at Indiana University School of Medicine) mice leaving the capillary bed intact. Human skin, excised during routine abdominoplasty procedures, was cut into approximately  $2 \text{ cm}^2$  sections and placed into each murine wound using sutures to hold the tissue in place. A piece of petrolatum-infused gauze was placed over the wound followed by a piece of Telfa dressing and secured by elastic wrap. Sutures and dressings were removed after 10 days and grafts were fully healed by 12 weeks after engraftment (Figure 1 and ref. 11). The skin was treated

with either the IGF-1R inhibitor AG538 (EMD Millipore) twice weekly or dimethylsulfoxide (DMSO) vehicle twice weekly for 30 minutes before being UVB-irradiated using 4 Philips FS20T12 UVB broadband light sources as previously described (11) at approximately 2 minimal erythema doses ( $700 \text{ J/m}^2$ ) 5 times per week for 20 weeks.

The human skin xenografts were then excised and bisected. Half of each graft was snap frozen in liquid nitrogen and stored at  $-80^\circ\text{C}$  until processed. The remaining portion of the graft was placed in 10% buffered formalin for an hour followed by storage in 70% ethanol until paraffin-embedded sectioned, and stained.

**Clinical trial oversight.** These studies consisted of 2 separate clinical trials. The first was a single FLR treatment to a localized area of either sun-exposed forearm or sun-protected hip/buttock skin, which took place at both the Indiana University School of Medicine Department of Dermatology and the Wright State University Department of Pharmacology & Toxicology in the Boonshoft School of Medicine. The second trial was an investigator-initiated, single site, randomized single-blinded study performed at the Dayton Veterans Administration Medical Center and the Wright State University Department of Pharmacology and Toxicology in the Boonshoft

**Table 2. Cutaneous malignancies in participants**

Participant no.	Pathology report	Arm where lesion was identified	Time period (months)
36	SCC, well-differentiated type	Untreated	3
30	BCC, superficial type	Untreated	6
31	SCC, well-differentiated type	Untreated	6
36	SCC, moderately differentiated type	Untreated	6
11	BCC, superficial type	Untreated	12
14	SCC in situ	Untreated	12
19	BCC, nodular type	Untreated	12
20	BCC, superficial type	Untreated	12
25	SCC in situ	Untreated	12
33	SCC, well-differentiated type	Untreated	12
47	SCC, well-differentiated type	Untreated	12
1	SCC in situ	Untreated	18
10	SCC in situ	Untreated	18
19	BCC, nodular type	Untreated	18
38	SCC, moderately differentiated type	Untreated	18
12	SCC in situ	Untreated	24
19	SCC in situ	Untreated	24
20	SCC, moderately differentiated type	Untreated	24
33	SCC, well-differentiated type	Untreated	24
33	SCC, well-differentiated type	Untreated	24
39	SCC, well-differentiated type	Untreated	24
46	SCC in situ	Untreated	24
14	SCC, well-differentiated type	Untreated	36
30	SCC in situ	Treated	6
19	SCC, well-differentiated type	Treated	24

School of Medicine testing the efficacy of FLR to treat NMSCs. Studies were approved by the institutional review boards of both institutions. Both studies were conducted in accordance with the Declaration of Helsinki principles.

For the first localized FLR treatment study, specific requirements for inclusion and exclusion criteria were identical to our previous study which tested FLR on a small (5 × 5 cm<sup>2</sup>) area of forearm skin (10). Briefly, potential individuals were excluded if they had diabetes mellitus, wound healing, or scarring disorders (e.g., keloids), or were on any topical or oral immunomodulators. None of the participants had a recent (6 months or less) history of significant commercial or medical UV exposure, any cryotherapy in the past year to the areas, nor any field treatment to upper extremities by topical 5-fluorouracil, topical NSAIDs, imiquimod, or topical photodynamic therapy.

The second study evaluated the safety and effectiveness of a single treatment with FLR on upper extremity skin of aged participants with extensive AK. This study was registered at ClinicalTrials.gov (NCT03906253). Forty-eight nondiabetic volunteers (47 males, 1 female; age ≥ 60 years) with Fitzpatrick types I and II skin with at least 5 AKs on each forearm/wrist were recruited from patients at the Dayton Veterans Administration Medical Center dermatology clinics. AKs were identified as dry, scaly patches of skin that are rough to the touch and often having a distinct color from the surrounding skin. All of the AKs were small (< 3 mm; grades I or II). Specific requirements for inclusion and exclusion criteria were identical to the above and have been previously published (15).

**Trial procedures.** All participants were thoroughly briefed on the risks and benefits of participating in the study and signed an informed consent statement attesting to their willful participation. Volunteers who met the criteria for inclusion in this study had the AKs on their bilateral dorsal forearms/wrists and dorsal hands (excluding digits, see Figure 6A) mapped, counted, and graded (grades I and II, ref. 16). Forty-eight individuals were enrolled in the study; 26 individuals underwent treatment to the right arm and 22 individuals underwent treatment to the left arm. Following shaving to remove hair from the planned laser treatment site, the skin was cleaned with isopropyl alcohol and 4% xylocaine cream was placed for 30 minutes for anesthesia. The area was then treated with one pass (16% coverage) using 120 mJ of energy per microspot with the largest coverage (~1 × 2 cm) (Pearl Fractional Laser, Cutera). The Pearl Fractional Laser is a 2790 nm yttrium scandium gallium garnet ablative fractional resurfacing device that thermally ablates microscopic columns of epidermal and dermal tissue in regularly spaced arrays. White petrolatum was placed on the wounded skin and the area was covered with clear plastic wrap until the individual returned home. All participants were also reminded to avoid significant sun exposure and to use sun protection/sunscreen.

Participants were given written wound care instructions to include white petrolatum and asked to return in 3 months and every 6 months afterwards. At the initial appointment and at all follow-up times, the areas on both arms were photographed and AKs counted/mapped in blinded fashion with the measurer unaware of which arm had been treated with FLR. Participants were also questioned as to any adverse effects of the laser treatment. Any lesions suspicious for NMSCs were biopsied and the biopsies were evaluated by dermatopathologists who had no knowledge of the study. Participants were removed from the study if more than 20 AKs were present on 1 arm at a follow-up appointment.

**Randomization and blinding.** The participants were divided into 2 cohorts. One group was treated with FLR on the left side, the other on the right side. An unblinded research coordinator assigned the treatment arm based on odd/even social security number. Photography and AK counting/mapping was conducted in a blinded fashion, as described above.

**Statistics.** Experimental data are depicted as plus or minus standard deviation. Differences between paired samples were determined by a 2-tailed Student *t* test. For all figures, *P* values are presented in the figure where possible or in the figure legend. If *P* values are not indicated on the graph, then there was no statistically significant difference between data shown.

**Study approvals.** All studies involving mice were approved by the IACUC of Indiana University School of Medicine. All studies involving humans were approved by either the IRB at Indiana University School of Medicine or at Wright State University and followed Declaration of Helsinki principles. Volunteers provided written informed consent before enrollment in studies.

## Author contributions

All of the authors have made substantial contributions to the acquisition, analysis, or interpretation of the data. In addition, all of the authors have contributed to the drafting or editing of the manuscript and gave their approval for the version submitted. DFS, JBT, MGK, DAL, JJW, RC, and CAR designed the experiments. DFS, DS, SST, and JBT conducted the animal studies. DFS, DS, AZ, ML,

DAL, AJC, MGK, CK, JW, MM, and JBT designed the laboratory protocols. RC, EC, ARW, CK, JJW, CAR, ML, JW, SB, RG, RH, and JBT contributed to patient consent and care. DFS, JBT, RC, MGK, KYT, MK, CK, MM interpreted the data. DFS and JBT verified all of the underlying data.

## Acknowledgments

This work was supported by grants from the National Institutes of Health (R01 HL062996 to JBT; R01 AG048946 to JBT and DFS) and a VA Merit Award (1101CX000809 to JBT). The content is

solely the responsibility of the authors and does not necessarily represent the official views of the National Institutes of Health nor the US Veterans Administration. Trial registered at ClinicalTrials.gov (NCT03906253). JJW was a recipient of an ASLMS educational grant, and this work was presented in partial form as an abstract at the 2019 ASLMS meeting.

Address correspondence to: Jeffrey B. Travers, 3640 Colonel Glenn Highway, Dayton, Ohio 45345, USA. Email: jeffrey.travers@wright.edu.

- Karimkhan C, et al. It's time for "keratinocyte carcinoma" to replace the term "nonmelanoma skin cancer". *J Am Acad Dermatol*. 2015;72(1):186-187.
- Rogers HW, et al. Incidence estimate of nonmelanoma skin cancer (Keratinocyte Carcinomas) in the U.S. population, 2012. *JAMA Dermatol*. 2015;151(10):1081-1086.
- Yeung H, et al. Use and cost of actinic keratosis destruction in the Medicare Part B Fee-for-Service population, 2007-2015. *JAMA Dermatol*. 2018;154(11):1281-1285.
- Ho WL, Murphy GM. Update on the pathogenesis of post-transplant skin cancer in renal transplant recipients. *Br J Dermatol*. 2008;158(2):217-224.
- Kraemer KH. Sunlight and skin cancer: another link revealed. *Proc Natl Acad Sci U S A*. 1997;94(1):11-14.
- Garcovich, et al. Skin cancer epidemics in the elderly as an emerging issue in geriatric oncology. *Aging Dis*. 2017;8(5):643-661.
- Lewis DA, et al. A new paradigm for the role of aging in the development of skin cancer. *J Invest Dermatol*. 2008;129(3):787-791.
- Lewis DA, et al. The IGF-1/IGF-1R signaling axis in the skin: a new role for the dermis in aging-associated skin cancer. *Oncogene*. 2010;29(10):1475-1485.
- Lewis DA, et al. Reversing the aging stromal phenotype prevents carcinoma initiation. *Aging (Albany NY)*. 2011;4(4):407-416.
- Spandau DF, et al. Fractionated laser resurfacing corrects the inappropriate UVB response in geriatric skin. *J Invest Dermatol*. 2012;132(6):1591-1596.
- Loesch MM, et al. Insulin-like growth factor-1 receptor regulates repair of ultraviolet B-induced DNA damage in human keratinocytes in vivo. *Mol Oncol*. 2016;10(8):1245-1254.
- Kemp M, et al. Insulin-like growth factor 1 receptor signaling is required for optimal ATR-CHK1 kinase signaling in ultraviolet B (UVB)-irradiated human keratinocytes. *J Biol Chem*. 2017;292(4):1231-1239.
- Ratushny V, et al. From keratinocyte to cancer: the pathogenesis and modeling of cutaneous squamous cell carcinoma. *J Clin Invest*. 2012;122(2):464-472.
- Tavakkol A, et al. Expression of growth hormone receptor, insulin-like growth factor 1 (IGF-1) and IGF-1 receptor mRNA and proteins in human skin. *J Invest Dermatol*. 1992;99(3):343-349.
- Chen R, et al. Single ablative fractional resurfacing laser treatment for forearm actinic keratosis: six month follow-up data from an intrapatient comparison between treated and untreated sites. *Lasers Surg Med*. 2020;52(1):84-87.
- Rowert-Huber J, et al. Actinic keratosis is an early in situ squamous cell carcinoma: a proposal for reclassification. *Br J Dermatol*. 2007;156(Suppl 3):8-12.
- Thompson SC, et al. Reduction of solar keratosis by regular sunscreen use. *N Engl J Med*. 1993;329(16):1147-1151.
- Krtolica A, et al. Senescent fibroblasts promote epithelial cell growth and tumorigenesis: a link between cancer and aging. *Proc Natl Acad Sci U S A*. 2001;98(21):12072-12077.
- Parrinello S, et al. Stromal-epithelial interactions in aging and cancer: senescent fibroblasts alter epithelial cell differentiation. *J Cell Sci*. 2005;118(Pt 3):485-496.
- Lago JC, Puzzi MB. The effect of aging in primary human dermal fibroblasts. *PLoS One*. 2019;14(7):e0219165.
- Lewis DA, et al. UVB-induced senescence in human keratinocytes requires a functional IGF-1R and p53. *Mol Biol Cell*. 2008;19(4):1346-1353.
- Nomura T, et al. Induction of cancer, actinic keratosis, and specific p53 mutations by UVB light in human skin maintained in severe combined immunodeficient mice. *Cancer Res*. 1997;57(11):2081-2084.
- Soballe PW, et al. Carcinogenesis in human skin grafted to SCID mice. *Cancer Res*. 1996;56(4):757-764.
- Al-Gayyar MMH, et al. The therapeutic effects of nicotinamide in hepatocellular carcinoma through blocking IGF-1 and effecting the balance between Nrf2 and PKB. *Biomed Pharmacother*. 2019;112:108653.
- Botusan IR, et al. Deficiency of liver-derived insulin-like growth factor-1 (IGF-1) does not interfere with the skin wound healing rate. *PLoS One*. 2018;13(3):e0193084.
- Jetter N, et al. Field cancerization therapies for management of actinic keratosis: a narrative review. *Am J Clin Dermatol*. 2018;19(4):543-557.
- Iyer S, et al. Full face laser resurfacing provides long-term effective prophylaxis against AKs and may reduce the incidence of AK related squamous cell carcinoma. *Lasers Surg Med*. 2004;34(2):114-119.
- Krbanjec A, et al. How wounding via lasers has potential photocarcinogenic preventative effects via dermal remodeling. *Curr Dermatol Rep*. 2016;5(3):222-227.
- Dodson JM, et al. Malignant potential of actinic keratosis and the controversy over treatment. *Arch Dermatol*. 1991;127(7):1029-1031.
- Marks R, et al. Malignant transformation of solar keratoses to squamous cell carcinoma. *Lancet*. 1988;1(8589):795-797.
- Criscione VD, et al. Actinic keratoses: natural history and risk of malignant transformation in the Veterans Affairs Topical Tretinoin Chemoprevention Trial. *Cancer*. 2009;115(11):2523-2530.
- Chen AC, et al. A phase 3 randomized trial of nicotinamide for skin-cancer chemoprevention. *N Engl J Med*. 2015;373(17):1618-1626.
- Rosenberg AR, et al. Skin cancer precursor immunotherapy for squamous cell carcinoma prevention. *JCI Insight*. 2019;4(6):e125476.